

**NEW TECHNIQUE FOR CORRECTING BOTH  
INCONTINENCE AND CYSTOCELE:  
T.I.C.T.  
(TENSION-FREE INCONTINENCE CYSTOCELE TREATMENT)**

**V. LEANZA<sup>1</sup>, N. GASBARRO<sup>2</sup>, S. CASCHETTO<sup>1</sup>**

<sup>1</sup> 1<sup>ST</sup> OBSTETRICS AND GYNECOLOGY DPT  
CATANIA UNIVERSITY

<sup>2</sup> OSPEDALE CIVICO U.O. OBSTETRICS AND GYNAECOLOGY DPT  
ASL 7 CHIVASSO (TORINO)

*Keywords: Cystocele, T.I.C.T., stress urinary incontinence; genital prolapse; mesh.*

**SUMMARY:** *The purpose of this retrospective study is to evaluate the safety and the efficacy of a new surgical procedure for correcting both incontinence and cystocele. This method of Tension-free Incontinence Cystocele Treatment (T.I.C.T.) consists in using a polypropylene fly shaped mesh made up of a central body (positioned under both the urethra and the bladder) and two wings (which cross the Retzius and reach the suprapubic area after being pulled up with a modified Stamey needle, under digital control). Seventy patients with stress urinary incontinence and severe cystocele underwent the T.I.C.T. procedure. Their mean age was 56 years (range 40-78), the average follow up was 18 months (range 2-36 months). The objective cure rate was 90% for incontinence and 94.3% for cystocele. No intra-operative complications occurred. Postoperative complications included 2 cases (3%) of voiding difficulty, one case of de novo instability, and one case of erosion and granuloma. Neither bladder perforation nor vascular damage was found. These data show the low risks and the good results of this treatment.*

## INTRODUCTION

Tension-free vaginal tape (T.V.T.) was introduced by Ulmsten in 1996, on the basis of experimental and clinical investigations in order to obtain a physiologic mechanism of closure and opening of the urethra in case of stress urinary incontinence (S.U.I.) due to hypermobility (1). Several studies show the high rate of cure (90%) on S.U.I. after using T.V.T (2,3), nevertheless this technique does not correct cystocele, but only urethrocele and/or hypermobility.

Other procedures are required when the defect concerns not only the level III fibres (fusion) of anterior compartment, but also the level II (attachment) (4). With traditional techniques of cystocele repair the recurrence rate ranges 50-60%, whereas after using polypropylene net the few cases of failure (7.3%) are due to migration of the mesh (5). The pubovaginal sling procedure has good long-term results for cure of stress incontinence (6,7,8) but it has intrinsic elements of obstruction.

Nicita (9) (1998) reported a new operation for genitourinary prolapse consisting in making use of a mesh which is anchored with polyglycolic stitches to the arcus tendineus of the endopelvic fascia transversally, to the bladder neck anteriorly and to the uterine neck posteriorly. The mechanism used is not tension free, because the patch is fixed to surrounding tissues.

We propose a new technique to treat both S.U.I. and cystocele, the originality of which consists in using only one fly shaped mesh with a ten-

sion-free mechanism; the wings of the mesh reach through the periurethral space via Retzius to the suprapubic skin whereas the body is placed under the urethra and bladder; the point of highest resistance of the mesh coincides with middle urethra.

## MATERIALS AND METHODS

Seventy patients with stress urinary incontinence and cystocele underwent the T.I.C.T. procedure. Their mean age was 56 years (range 40-78), the average follow up was 18 months (range 2-36 months). The preoperative investigation included pelvic examination, urinalysis, pad weighing test, urodynamics, cystoscopy, pelvic and abdominal ultrasounds with evaluation of the gynaecologic apparatus together with the lower and upper urinary tract. Stress incontinence types were classified according to Blaivas (10). As for severity of S.U.I., grading of incontinence was assessed as follows: grade I (severe stress), grade II (moderate stress), grade III (mild stress), latent incontinence (positive Bonney test after filling to 200 cc with Leak Point Pressure  $>60$  cm H<sub>2</sub>O and closure pressure  $>20$  cm H<sub>2</sub>O) and potential incontinence (positive Bonney test after filling to 200 cc with Leak Point Pressure  $<60$  cm H<sub>2</sub>O and closure pressure  $<20$  cm H<sub>2</sub>O).

Pelvic prolapse was classified according to H.W.S. (11); vaginal hiatus, perineal body, vaginal length were also evaluated.

The patients enrolled in this study were suffering from both S.U.I. and cystocele.

Of 70 patients 20 (28.6%) had grade

I incontinence, 28 (40%) grade II, 11 (15.7%) grade III, 5 (7.1%) latent and 6 (8.6%) were potentially incontinent.

Twenty (28.6%) patients complained of II degree cystocele, 40 (57.1%) III degree, 10 (14.3%) IV degree. Regarding the apical defect 16 (22.9%) patients complained of I degree uterine prolapse, 30 (42.9%) patients of II degree, 9 (12.8%) of III degree, and in 15 (21.4%) the uterus was not prolapsed. With respect to the posterior compartment, 20 (28.6%) patients complained of I degree rectocele, 30 (42.9%) of II degree, 8 (11.4%) of III degree, and in 12 (17.1%) patients no posterior defect was found. All the defects were repaired during the operation vaginally, and the abdominal route was never requested owing to complication. The uterus was removed in 55 (78.6%) cases. As for apical suspension, a levator cuff suspension together with axial suspension of vaginal apex to the ligamentous complex (uterosacral-cardinal-round) was performed in 15 (21.4%) cases, whereas in the other 40 patients undergoing hysterectomy only axial suspension was performed. Rectocele was repaired, after removing redundant vagina and drawing close the levator ani and pubococcygeal muscle. The rectal fascia was repaired and both rectal fascia and vaginal wall were anchored to the centrum tendineum perinei. Great attention had to be paid to avoid narrowing the introitus. Posterior repair was performed in 58 (82.9%) cases.

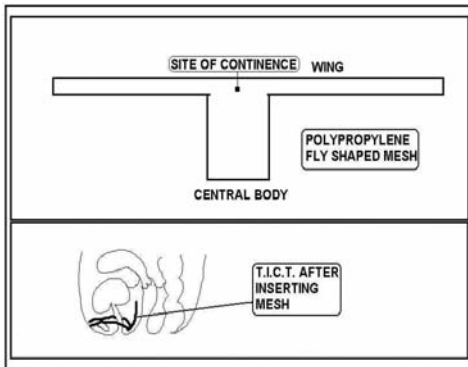
The postoperative investigation included a detailed study of the urogynaecological symptoms, the use of a questionnaire according to Korman

(12) and Trokman (13), a physical examination to identify pelvic floor defects according to the H.W.S. (11), a quantification of the pelvic organ prolapse according to Bump (14), a urodynamic test and pelvic and abdominal ultrasounds with evaluation of the gynaecologic apparatus together with the lower and upper urinary tract. The postoperative assessment also included surgical time, ancillary procedures, intra- and postoperative complications, hospital stay and evaluation of the outcome. Incontinence was evaluated subjectively and objectively, prolapse recurrence only objectively. Incontinence was subjectively cured when no leakage of urine occurred during stress, improved when use of pads decreased, unvaried when the situation was unchanged, worsened when more pads a day were requested. Objective incontinence was considered cured when no urinary leak was observed during the cough test after filling the bladder to at least 300 cc. The pelvic defect was considered cured when no prolapse appeared during examination after stress, improved in case of decreased entity of the prolapsed compartment. Follow-up visits were scheduled at discharge, after 1 month and then every six months.

Twenty-four (34.3%) of the patients also complained of urgency, 10 (14.3%) of frequency, 5 (7.1%) of urge incontinence and 7 (10%) of obstruction owing to a kinking effect. The mean Q tip test result was 50 degrees (range 10-100). All the patients received antibiotic therapy. Thirty-three (47.1%) patients underwent peripheral anaesthesia (epidural or spinal), for the remaining 37 (52.9%) general

anaesthesia was used. When discharged, oestrogen replacement therapy was recommended when ovaries were removed, and the patient was always instructed in practising physiotherapy and perineal resistance exercises.

**Fig. 1 - Shape of the T.I.C.T. mesh before and after insertion**



The patient is placed on the operating table in a lithotomic position. A longitudinal incision is performed on the anterior vaginal wall, from the middle urethra to the uterine neck (or to anterior vaginal apex in case of previous hysterectomy). Paraurethral access is obtained laterally and parallel to the middle urethra by grasping the vaginal skin with hooks anchored to the Scott retractor. Preparation of the avascular space is carried out, which allows contact with the inferior medial edge of the ischial ramus and then the urogenital diaphragm is perforated with the index finger or a closed clamp. The fingertip penetrates into the Retzius space up to the abdominal rectus muscle aponeurosis. A macroporous polypropylene long winged fly mesh is prepared (fig.1). The wings are about

30 centimetres long and 1.5 wide. The size of the body is modulated according to severity of cystocele (mean size 5.5 centimetres in length and 4 in width). Folds of the net are to be avoided. A 2 mm symmetric hole is made on the suprapubic area 2 cm obliquely and above the anterior commissura. A modified Stamey needle with eye is introduced from the suprapubic space into the previous hole. The wing of the mesh anchored by thread to needle eye is passed to suprapubic area and left tension free. Same steps on other side. A spy thread is placed in the centre of the mesh longitudinally. If the patient is under loco-regional anaesthesia, modulation of the mesh is to be performed with cough test after introducing 300 cc of saline solution; in case of general anaesthesia the mesh is left loose-fitting. Cystoscopy is always carried out to avoid obstruction of the urethra and accidental perforation. After putting a further spy thread on both ends of the wings, extremities of the mesh are cut and then hidden into subcutaneous tissue, by means of raising the skin with forceps. Neither stitches nor glue are used in the skin. Redundant vaginal tissue is removed and the anterior wall is closed with a continuous vicryl® suture. When patients with potential or latent incontinence were operated, the mesh was left as loose as possible. When an apical defect coexists, a levator cuff suspension is performed, after removing the uterus, with vaginal approach. Posterior colporrhaphy is to be performed when rectocele is observed. The indwelling catheter is removed the day after and if the patient urinates regularly, the residual urine is less than

50cc and no incontinence persists, the three spy threads are removed.

### RESULTS

The mean follow up was 18 months (range 2-36 months). No blood transfusion was requested. No obstruction requiring catheterisation was found.

The average hospital stay was 5 days.

With the subjective method incontinence was cured in 64 (91.4%) patients, improved in 3 (4.2%) and in 3 (4.2%) it was unchanged..

Objectively, S.U.I. was cured in 63 (90%), improved in 4 (5.7%) cases.

The urodynamic findings after the operation were not significantly different from the preoperative ones (Table 1).

**Table 1.** Urodynamic findings before and after T.I.C.T.

Urodynamic parameters	Preoperative	Postoperative	P
M.U.C.P.(cm H <sub>2</sub> O)	40 ± 16	38 ± 14	N.S.
F.U.L.(mm)	25 ± 5	24 ± 6	N.S.
F.R.(m/sec)	24 ± 8	23 ± 7	N.S.
V.T.(sec)	33 ± 18	34 ± 16	N.S.

M.U.C.P.(Maximal Urethral Closure Pressure);

F.U.L.(Functional Urethral Length);

F.R.(Mean Flow Rate);

V.T.(Voiding Time);

N.S.(Not Significant)

The mean Q tip test result was 23 degrees (range 10-42).

Recurrence of cystocele was found only in 4 (5.7%) cases, among which 3 (4.2%) I degree cystocele and only 1 II degree cystocele were found at the first control and these findings remained unchanged. No cases of vault prolapse were found. Rectocele was discovered in 5 (7.1%) cases. During follow-up no other pelvic procedures were ever requested.

The mean time required for the T.I.C.T. was 25 minutes (range 15-35); for entire surgery 50 minutes (range

15-70). Preoperative and postoperative data showed a loss of 0.8 g/dl of haemoglobin.

There were no cases of bladder perforation, Retzii haematoma, abscess formation, postoperative haemorrhage or retropubic bleeding requiring laparotomy. Post operative complications included 2 (3%) cases of voiding difficulties, one case of *de novo* instability and one case of erosion and granuloma. The two cases of voiding difficulties were solved: the former by

means of pulling vaginal spy thread the day after, the latter with sympatholytic, respectively. *De novo* instability improved with parasympatholytic drugs, whereas erosion needed one centimetre excision of protruding mesh but the pelvic floor was not compromised and, finally, granuloma was removed under local anaesthesia. Frequency was found in 8 (11,4%) cases.

Urgency was found in 15 (21.4%) and urge incontinence in 2 (2.8%) cases.

### DISCUSSION

Tension free criteria in correcting pelvic floor functional alterations have been spreading in the last decade. T.V.T. is a relatively new technique introduced in surgical practice in 1994-1995 and within a few years more than 150,000 operations have been carried out with this method (3).

The T.I.C.T. procedure is not an alternative to T.V.T., but it is a good procedure only in the selected cases when stress urinary incontinence is associated with cystocele.

The objective of T.I.C.T. is to maintain good support without tension not only under the middle urethra but also in the whole anterior compartment. The mesh is positioned in such a way so the wings reach from the vagina to the suprapubic area and the body lies along the anterior vaginal wall. The greatest resistance of the mesh is in correspondence with the continence site, owing to the connection of anterior part of the body with the wings, whereas the posterior part of the mesh is completely free in order to allow both physiologic mobility of the anterior

or compartment and good simultaneous support. Abdominal-perineal continuity of the mesh is essential to avoid migration of cystocele covering the mesh, as occurs when isolated mesh is used to correct bladder prolapse (5).

Spy threads are used to avoid either hypo- or hyper-correction, even though with good experience they are not absolutely necessary.

Complications are uncommon because T.I.C.T. is not a blind operation, but a finger guided procedure. Leaving the suprapubic hole into which the needle penetrates, without either stitches or glue, is optimal aesthetically as well as a good way of draining to avoid contemporary Retzii haematoma. In our experience, the subjective cure of 91.4% for S.U.I. as well as the objective cure of 90% for S.U.I. and of 94.3% for cystocele is satisfactory.

Regarding erosion of the mesh, it was suggested that this sort of complication is due to the exposed surface and to the distance that separates the mesh from the vaginal scars (15), moreover macroporosity is an important factor for making a physiologic cellular diaporesis possible.

Complications due both to bladder perforation or obstruction are avoided because stitches are not used and the tension free mechanism is employed. Regarding primitive defects of other pelvic compartments, we may say that T.I.C.T. corrects only central or lateral anterior defects, whereas it does not correct apical or posterior prolapse. Every primitive defect needs a specific correction of its own compartment. Indeed in case of uterine prolapse, apical descensus was repaired by apical suspension after removing the uterus;

we performed levator cuff suspension when the ligamentous apparatus was inadequate to obtain a good anchorage to the vaginal apex; in other cases axial suspension to the ligamentous complex was carried out. Cardinal and uterosacral ligaments are essential in maintaining the apical compartment in site, whereas the round ligament is not as important as the former, but its anchorage to the antero-lateral wall of the vaginal vault makes it possible to prevent a bulging lip effect.

Concerning anaesthesia, we believe peripheral anaesthesia is optimal for regulating the tension free mechanism, but when general anaesthesia is used, mesh should be left loose in order to

avoid urinary obstruction and the results will be just as satisfactory.

The synthetic mesh has even been used by general surgeons to achieve tension-free repair of abdominal wall hernia and it has resulted in a significant reduction of postoperative pain as well as the number of recurrences (16). Apart from the value of the technique used, the employment of meiotragic tissue brings with itself intrinsic seeds of failure. T.I.C.T. seems to be a safe and effective procedure both for functional (S.U.I.) and anatomic (cystocele) defects of the anterior compartment but further investigations have to be carried out.

Correspondence to  
Prof. V. Leanza  
Via Garibaldi 1  
98033 Cesarò (ME)  
Fax 095-316833 Clin.Ost. Catania  
E-MAIL [leanza@tiscalinet.it](mailto:leanza@tiscalinet.it)

## REFERENCES

- 1 - ULMSTEN U, HENRIKSON L, JOHNSON P,VARHOS G.:  
*An ambulatory surgical procedure under local anesthesia for treatment of female urinary incontinence.*  
Int Urogynecol J 1996;7:81-86.
- 2 - MESCHIA M, PIFAROTTI P, BERNASCONI F, GUERCIO E, MAFFIOLINI M, MEGATTI F, SPREADICO L. :  
*Tension-Free Vaginal Tape: Analysis of Outcomes and Complications in 404 Stress incontinent Women.*  
Int Urogynecol J (suppl 2) 2001;S24-S27.
- 3 - ULMSTEN U.:  
*An introduction to Tension-Free Vaginal Tape (TVT)- A New Surgical Procedure for Treatment of Female Urinary Incontinence.*  
Int Urogynecol J (Suppl2) 2001 ;S3-S4.
- 4 - DE LANCEY J O I.:  
*Anatomic Aspects of vaginal eversion after hysterectomy.*  
Am J Obstet Gynecol 1992; 166:1717-28.
- 5 - ADILE B, GUGLIOTTA G, LOBUE A, CAPUTO A.:  
*La riparazione del cistocele mediante rete di prolene tension free.*  
Urogynaecologia international Journal: 2000;Vol.14 n.1:75-76.
- 6 - MC GUIRE EJ. and LYTTON B.:  
*Pubovaginal sling procedure for stress incontinence.*  
J Urol., 1978; 119.:82-197.8
- 7 - BLAIVAS JG and JACOBS BZ.:  
*Pubovaginal fascial sling for the treatment of complicated stress urinary incontinence.*  
J Urol., 1991;145:1214.
- 8 - TAKUMI Y, GAAKU A, MASUDA H,TSUKAMOTOT, NAGAHAM K, NAGAMATSU H. :  
*The correlation of type 2 stress incontinence with polytetrafluoroethylene patch sling: 5 year mean follow-up.*  
J Urol., 1998;160:746-749.
- 9 - NICITA G.:  
*A new operation for genitourinary prolapse.*  
J Urol., 1998;160:741-745.
- 10 - BLAIVAS JG, OLSSON CA.:  
*Stress Incontinence classification.*  
J Urol. 1988;139:727.
- 11 - BADEN WF, WALZER TA. :  
*Genesis of the vaginal profile: a correlate classification of vaginal relaxation.*  
Clin Obstet Gynecol 1972;15:1048-1054.
- 12 - KORMAN HI, SIRLS LT, KIRKEMO AK.:  
*Success rate of modified Pereyra bladder neck suspension determined by outcomes analysis.*  
J Urol. 1994;152:1453.
- 13 - TROCKMAN BA, LEACH GE, HAMILTON J, SAKAMOTO M, SANTIAGO L, ZIMMERN PE.:  
*Modified Pereyra bladder neck suspension :10-year mean follow-up using outcomes analysis in 125 patients.*  
J Urol.1995;154:1841.
- 14 - BUMP RC, MATTIASSON A, BO K.:  
*The standardization of terminology of female pelvic organ prolapse and pelvic floor dysfunction.*  
Am J Obstet Gynecol 1996;175:10.
- 15 - CERVIGNI M, NATALE F.:  
*The use of synthetics in the treatment of pelvic organ prolapse.*  
Current Opinion in Urology 2001,11:429-435.
- 16 - AMID PK.:  
*Classification of biomaterials and their related complications in abdominal wall hernia surgery.*  
Hernia 1997,1:15-21.