

Management of stress urinary incontinence using transobturator tape: a case series

Suskhan Djusad, Surahman Hakim, Tyas Priyatini, Fernandi Moegni, Alfa Putri Meutia, Yudhistya Ksyatria, I Gede Manu
Division of Urogynecology and Reconstruction, Department of Obstetrics and Gynecology, Faculty of Medicine, University of Indonesia, Dr. Cipto Mangunkusumo National Central Public Hospital, Jakarta, Indonesia

Abstract

Urinary incontinence is a health problem for women and the elderly, both physically and psychologically. To cure it, mid-urethral sling surgery is used. Moreover, the transobturator tape (TOT) appears to reduce the incidence of bladder injuries. This

Correspondence: Suskhan Djusad, Division of Urogynecology and Reconstruction, Department of Obstetrics and Gynecology, Faculty of Medicine, University of Indonesia, Dr. Cipto Mangunkusumo National Central Public Hospital, Jakarta, Indonesia.
E-mail: suskhan007@yahoo.co.id

Key words: stress urinary incontinence, transobturator tape, midurethral sling surgery, TVT obturator, involuntary leakage.

Contributions: SD, conception and design of the study, acquisition, analysis, and interpretation of data, drafting of the manuscript and editing, funding acquisition; SH, conception and design of study, acquisition of data, drafting of the manuscript, operator; TP, acquisition, analysis, and interpretation of data, drafting of the manuscript; FM, APM, methodology, supervision, review and editing; YK, operator, editor; IGM, writing and editing of the manuscript.

Conflict of interest: the authors declare no potential conflicts of interest.

Ethics approval and consent to participate: the ethics approval in our institution in this study publication had been obtained (891/UN2.F1/ETIK/PPM.00.02/2024).

Patient consent for publication: written informed consent was obtained for publication, including any accompanying images.

Funding: none.

Availability of data and materials: due to the nature of the research, supporting datasets are not available.

Received:

Accepted:

This work is licensed under a Creative Commons Attribution NonCommercial 4.0 License (CC BY-NC 4.0).

©Copyright: the Author(s), 2024
Licensee PAGEPress, Italy
Urogynaecologia 2024; 36:315
doi:10.4081/uj.2024.315

Publisher's note: all claims expressed in this article are solely those of the authors and do not necessarily represent those of their affiliated organizations, or those of the publisher, the editors and the reviewers. Any product that may be evaluated in this article or claim that may be made by its

case series aims to assess the safety and efficacy of TOT at Dr. Cipto Mangunkusumo Hospital, Jakarta, Indonesia. We present eleven female patients diagnosed with stress urinary incontinence (SUI) and complaints of involuntary leakage during sneezing, coughing, or laughing. All patients underwent a TOT operation, which included a coughing test, pad test, residual volume, and urinalysis to rule out the infection. Out of the eleven patients, eight showed the reported urinary leakage at the first follow-up, and three did not attend the follow-up. The pad test post-operative results from five patients were obtained: four patients revealed 0 g in their pad test, while one showed 3 g. No patient experienced sling erosion during control or follow-up management. The low erosion rate was due to the usage of type 1 polypropylene meshes (macropore, monofilament), and the procedure was done with the correct technique. The sling TOT procedure seems effective and has the potential to become the new gold standard in the management of true SUI with low morbidity.

Introduction

Stress urinary incontinence (SUI) is the involuntary leakage of urine during physical exertion or activities (*i.e.*, sneezing, laughing, or coughing) without detrusor pressure.^{1,2} This condition has a significant adverse impact on the quality of life for the affected individuals.³ The prevalence of urinary incontinence in women is reported to be 15.1%, with stress-type incontinence affecting 24.9% of these women.¹

Midurethral sling surgery is currently the standard first-line management for SUI.⁴ The modification using transobturator tape (TOT) reduces the incidence of bladder and other organ injuries when done in an 'outside-in' approach.⁵ In 2003, de Leval *et al.* used an 'inside-out' approach, namely transvaginal tape-obturator (TVT-O).⁶ TOT was thought to have high cure rates with low morbidity.^{7,8} In this case series, we present an assessment of the safety and efficacy of the transobturator procedure as the treatment of SUI in our hospital.⁶

Case Series

This study comprises a single-center case series involving eleven female patients with SUI who willingly participated in the program at Dr. Cipto Mangunkusumo General Hospital (RSCM), Jakarta, Indonesia. The diagnosis was established based on reported complaints, such as the involuntary loss of urine during sneezing, coughing, or laughing, without the presence of overactive bladder symptoms. Common symptoms of SUI, such as the involuntary leakage of urine during physical activities, were considered in the evaluation of the patients. Objective investigations included the coughing test, pad test, assessment of residual volume, and uri-

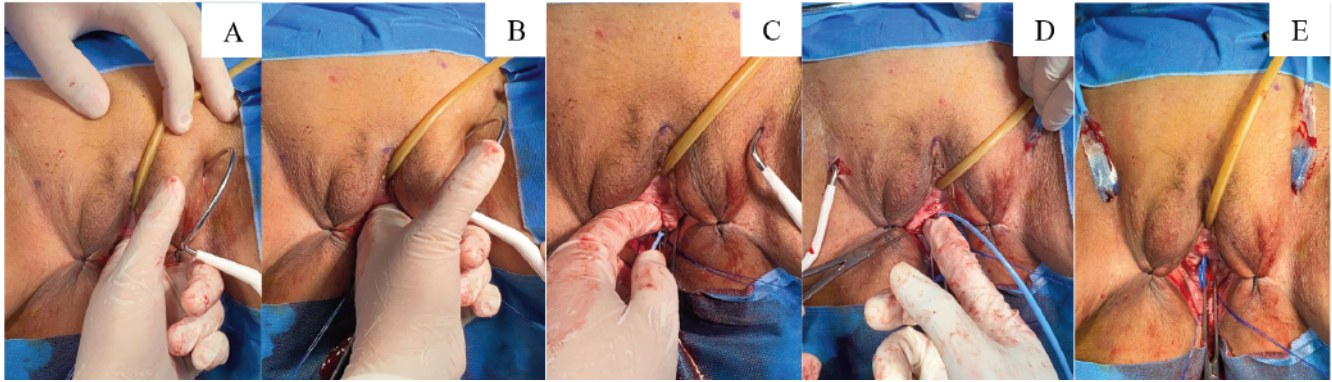


Figure 1. The step-by-step inside-out transobturator tape procedure. **A,B)** Mark the unfixed insertion point through the obturator foramen at the inferior ischiopubic ramus; **C)** create the vaginal incision, hold tightly with Allis tissue forceps, then place the index finger on the incision and the thumb at the closest point of the genito-crural fold; **D)** insert the tunneler tip on the obturator skin incision, keep it close up to the ischiopubic ramus; **E)** insert the tape and pull through the dissection and out of the obturator incision.

analysis to rule out infection. All patients underwent the TOT procedure (Figure 1), performed by urogynecology doctors and RSCM on-duty trainees. The average duration of the surgical procedure was 30 minutes. No postoperative voiding problems were found in our study.

Discussion

In our study, we observed no major complications, aligning with prior research indicating the absence of intraoperative complications such as bowel or large vessel injuries during the procedure.⁹ This finding is consistent with the recommendation from other studies that advocate for a more horizontal approach in performing TOT procedure as opposed to the U-shape retropubic sling. This modification aims to minimize contact with the urethra, thereby reducing the risk of complications.^{10,11} However, it is worth noting that adopting a more horizontal TOT axis might result in a slightly lower cure rate for SUI, although these studies did not specifically address the potential for complications.

During the first follow-up at RSCM, we found that eight out of eleven patients showed no evidence of urine leakage during coughing, laughing, or sneezing. Unfortunately, three patients did not attend the follow-up. Postoperative pad test data from five patients revealed that four had no leakage (0 g), while one showed a minor leakage of 3 g. None of the patients experienced sling erosion during control or follow-up management, attributed to the use of type I polypropylene meshes and the correct procedural technique.

Although urinary retention is reported in 1.5-15% of cases post-TOT procedure, our study did not observe any instances of urinary retention.^{8,12} This divergence may be attributed to our catheter removal protocol on the second day before patient discharge, which facilitates bladder retraining and reduces sling tension in the postoperative period.

Our study supports the notion that complications in the outside-in TOT approach are rare, in contrast to the estimated 16-17% occurrence of groin or thigh complications associated with the TVT-O inside-out approach.^{6,13} No complications were observed in our study, consistent with findings indicating that the outside-in TOT approach minimizes pain, potentially associated with the exit point of the needle in the TVT-O approach. Additionally, our study reported a mean age of 60.9 years for TOT patients, aligning with

the existing literature that suggests SUI predominantly affects perimenopausal or postmenopausal women.¹³

Conclusions

In conclusion, the outside-in TOT procedure emerges as a simple, effective, and minimally invasive alternative for managing SUI, demonstrating a low risk of intra- and post-operative complications. Our study emphasizes the importance of TOT slings, suggesting that other types may not yield comparable results. However, further research with a larger sample size is warranted to strengthen the findings of this study.

References

- Sumardi R, Mochtar CA, Junizaf, et al. Prevalence of urinary incontinence, risk factors and its impact: multivariate analysis from Indonesian nationwide survey. *Acta Med Indones* 2014;46:175-82.
- Chrysostomou A. The management of stress urinary incontinence using transobturator tapes in a tertiary hospital in South Africa. *Pelvipiperineology* 2012;31:82-6.
- Kwon BE, Kim GY, Son YJ, et al. Quality of life of women with urinary incontinence: a systematic literature review. *Int Neurourol J* 2010;14:133-8.
- Ulmsten U, Henriksson L, Johnson P, Varhos G. An ambulatory surgical procedure under local anesthesia for treatment of female urinary incontinence. *Int Urogynecol J Pelvic Floor Dysfunct* 1996;7:81-5.
- Delorme E. Transobturator urethral suspension: mini-invasive procedure in the treatment of stress urinary incontinence in women. *Prog Urol* 2001;11:1306-13. [Article in French].
- De Leval J. Novel surgical technique for the treatment of female stress urinary incontinence: transobturator vaginal tape inside-out. *Eur Urol* 2003;44:724-30.
- DeTayrac R, Deffieux X, Droupy S, et al. A prospective randomized trial comparing tension-free vaginal tape and transobturator suburethral tape for surgical treatment of stress urinary incontinence. *Am J Obstet Gynecol* 2004;190:602-8.

Retraction in: Am J Obstet Gynecol 2005;192:339.

8. Domingo S, Alamá P, Ruiz N, et al. Transobturator tape procedure outcome: a clinical and quality of life analysis of a 1-year follow-up. *Int Urogynecol J Pelvic Floor Dysfunct* 2007;18: 895-900.
9. Tamussino KF, Hanzal E, Kölle D, et al. Tension-free vaginal tape operation: results of the Austrian registry. *Obstet Gynecol* 2001;98:732-6.
10. Latthe PM, Foon R, Toozs-Hobson P. Transobturator and retropubic tape procedures in stress urinary incontinence: a systematic review and meta-analysis of effectiveness and complications. *BJOG* 2007;114:522-31.
11. Bukowski R, Malone FD, Porter F, et al. 5: Preconceptional folate prevents preterm delivery. *Am J Obstet Gynecol* 2007;197.
12. Deval B, Ferchaux J, Berry R, et al. Objective and subjective cure rates after trans-obturator tape (OBTAPE) treatment of female urinary incontinence. *Eur Urol* 2006;49:373-7.
13. Feng CL, Chin HY, Wang KH. Transobturator vaginal tape inside out procedure for stress urinary incontinence: results of 102 patients. *Int Urogynecol J Pelvic Floor Dysfunct* 2008;19:1423-7.

Non-commercial use only