

# Impact of vaginal submucosal platelet-rich plasma combined with non-cross-linked hyaluronic acid injections on dyspareunia and sexual satisfaction in a Hodgkin lymphoma cancer survivor: a case report

Salma Samir Omar,<sup>1</sup> Khaled F Elmulla,<sup>1</sup> Noran Abo Khadr,<sup>1</sup> Ahmed Ashour Badawy,<sup>2</sup> Eman Nabih Ramadan,<sup>1</sup> Ahmed Hassouna,<sup>3</sup> Lamia Heikal,<sup>4</sup> Waleed Arafat<sup>2</sup>

<sup>1</sup>Department of Dermatology, Venereology and Andrology, Faculty of Medicine, Alexandria University; <sup>2</sup>Department of Clinical Oncology and Nuclear Medicine, Faculty of Medicine, Alexandria University; <sup>3</sup>Consultant of Gynaecology and Obstetrics, Elshatby University Hospital, Alexandria University; <sup>4</sup>Department of Pharmaceutics, Faculty of Pharmacy, Alexandria University, Alexandria, Egypt

## Abstract

Vaginal atrophy is a commonly encountered problem among young cancer survivors. Patients suffer from vaginal dryness, irritation, and dyspareunia secondary to oestrogen deficiency. Oestrogen-

based hormone replacement therapy is effective, but unfortunately health concerns or contraindications in cancer survivors frequently limit its use. A 35-year-old female patient with dyspareunia that markedly affected her sexual relationship was referred to the gynaecology clinic. Treatment using topical oestrogen cream and sexual counselling were not successful. We treated her using two submucosal injections of PRP-non-cross-linked hyaluronic acid injections into the vestibule and lower third of the anterior vaginal wall mucosa, spaced a month apart. The patient reported marked reduction of dyspareunia and demonstrated an improvement of FSFI total score 1 month after the second injection. Both the patient and her husband showed an improvement of the index of sexual satisfaction score one month after the second injection compared to their pre-treatment scores. Examination of the vaginal mucosa showed improvement of thickness and integrity of the mucosa and increased lubrication. PRP-non-cross-linked hyaluronic acid submucosal injections can be effective for cancer therapy-related vaginal atrophy, coitus-related pain, and sexual satisfaction.

Correspondence: Salma S. Omar, Department of Dermatology, Venereology and Andrology, Faculty of Medicine, Elkhartoum square 21521, Alexandria University, Alexandria, Egypt.  
Tel.: +20.1227982197.  
E-mail: salma.samir@alexmed.edu.eg

Key words: platelet-rich plasma; vulvovaginal atrophy; cancer; hyaluronic acid.

Contributions: SO, supervision, writing the manuscript draft, revision; KE, NAK, supervision, revising the manuscript draft; AB, AH, LH, writing the manuscript, data collection; ER, writing the manuscript, data collection, manuscript revision; WA, supervision, shared in writing the manuscript, data collection.

Conflict of interest: the authors declare no conflict of interest.

Ethics approval and consent to participate: approval of the local ethics committee (IRB #00012098) was obtained (#0201349). Informed consent was obtained from the patient included in this study.

Patient consent for publication: the patient gave her written consent to use her personal data for the publication of this case report and any accompanying images.

Availability of data and materials: all data underlying the findings are fully available.

Received for publication: 25 March 2023.

Accepted for publication: 16 May 2023.

This work is licensed under a Creative Commons Attribution NonCommercial 4.0 License (CC BY-NC 4.0).

©Copyright: the Author(s), 2023  
Licensee PAGEPress, Italy  
Urogynaecologia 2023; 35:306  
doi:10.4081/uj.2023.306

*Publisher's note: all claims expressed in this article are solely those of the authors and do not necessarily represent those of their affiliated organizations, or those of the publisher, the editors and the reviewers. Any product that may be evaluated in this article or claim that may be made by its manufacturer is not guaranteed or endorsed by the publisher.*

## Introduction

As a result of improved cancer survival rates, more young female cancer survivors experience menopausal symptoms. Symptoms of vulvovaginal atrophy or genitourinary syndrome of menopause occur secondary to oestrogen deficiency caused by different cancer therapies (radiotherapy, chemotherapy, and surgery).<sup>1</sup>

The genitourinary syndrome of menopause (GSM) is a newer nomenclature for the condition previously known as vulvovaginal atrophy. It is characterized by a constellation of signs and symptoms resulting from diminished oestrogen.<sup>2</sup> Symptomatology includes genital symptoms (dryness, burning, itching), sexual symptoms (dyspareunia and impaired sexual function) and urinary symptoms (dysuria, frequency, urgency, recurrent urinary infections).<sup>3</sup> These symptoms negatively impact the quality of life of affected females, including sexual function, self-perception, and body image.<sup>4</sup>

Currently available therapies include vaginal lubricants and moisturizers, vaginal oestrogens and dehydroepiandrosterone (DHEA), systemic hormone therapy, and ospemifene.<sup>5</sup> However, such therapies are frequently ineffective or contraindicated in cancer survivors.<sup>6</sup> So, alternative non-hormonal approaches have been recently investigated to improve symptoms of vulvovaginal atrophy among cancer survivors with a history or at risk of gynecological cancers. Recently emerging energy-based devices as radiofrequency or laser sources, such as micro-ablative carbon dioxide (CO<sub>2</sub>; 10,600 nm) and non-ablative erbium-YAG (2940 nm) have been tried in the treatment of GSM.<sup>7,8</sup> A recent systematic review of nine studies concluded that fractional CO<sub>2</sub> laser was safe and

effective in treating vaginal atrophy and sexual dysfunction in women who survived gynecological cancers through its proposed action of thermal dependent matrix remodeling and angiogenesis which in turn increase vaginal elasticity, transudate fluid and mucosal integrity.<sup>3</sup> Combination of hyaluronic acid, curcumin, quercetin, and chondroitin sulphate is another non-hormonal oral medication that has been suggested to be effective in avoiding the recurrence of urinary tract infections associated with menopause<sup>9</sup> as well as in women in the reproductive age group.<sup>10</sup>

Additionally, vaginal injectables as autologous platelet-rich plasma alone or combined with hyaluronic acid (A-PRP-HA) may provide a new alternative therapy for the treatment of VVA and sexual dysfunction in postmenopausal women with history of cancer.<sup>11</sup> Platelet-rich-plasma is known for its potential rejuvenation effects in various tissues for different indications. This is mediated by the high concentrations of growth factors resulting in regeneration of epithelial cells and dermal collagen, restoration of dermal cellular functions, stimulation of angiogenesis, and nerve endings regeneration. These effects were proposed to aid in improving vulvovaginal elasticity, fluid volume, pH, epithelial integrity, moisture, and eventually sexual dysfunction.<sup>12,13</sup>

Hyaluronic acid is a high-molecular-weight non-sulphated glycosaminoglycan naturally present in various tissues. Hyaluronic acid serves important physiologic roles in living organisms, including maintenance of the viscoelasticity of connective tissues and tissue hydration, especially in the dermis, mucous membranes, and submucosal tissue layers.<sup>14</sup> Owing to its hydrating effects, HA is frequently used as an ingredient in topical lubricants or injected for conditions such as dyspareunia.<sup>14</sup>

## Case Report

A 35 old female complaining of dyspareunia presented to the gynaecology outpatient clinic. She gave a history of two previous vaginal deliveries. Her medical records revealed a history of stage IIIA Hodgkin's lymphoma with bulky pelvic lymph nodes for which she received chemotherapy; ABVD chemotherapy regimen [doxorubicin hydrochloride (Adriamycin), bleomycin sulphate, vinblastine sulphate, and dacarbazine] followed by consolidating radiotherapy for the pelvic nodes that led to ovarian suppression. Her menstrual periods stopped 2 months after completion of her treatment. She developed amenorrhea and her serum oestradiol and follicle stimulating hormone (FSH) levels were 10 pg/mL and 85.5 IU/L respectively. Consequently, she started to suffer from genitourinary symptoms of menopause. The most troublesome symptom was dyspareunia. She sought couple sexual counselling and applied topical oestrogen and topical hyaluronic acid gel but none were effective. Upon examination, her vaginal mucosa was thinned, dry and friable and vaginal fluid was scanty. A vaginal mucosal punch biopsy was obtained. Examination of the haematoxylin and eosin-stained section showed marked atrophy of vaginal epithelium (thinning and flattening of non-keratinized stratified squamous epithelium) with decrease in glycogen containing cells and loss of maturation (smaller cell size with less cytoplasm) on the surface. The lamina propria shows highly vascular fibrous tissue with increased hyalinization of collagen fibres. PAS stain of the histopathologic sections showed decrease in the positively stained glycogen containing cells confirming the diagnosis of vaginal mucosal atrophy (Figure 1A, B). We did not consider systemic hormone replacement therapy due to the positive family history of breast cancer obtained from the patient. We treated her by two vaginal submucosal injections of platelet-rich-plasma combined with non-cross-linked hyaluronic acid spaced one month apart.

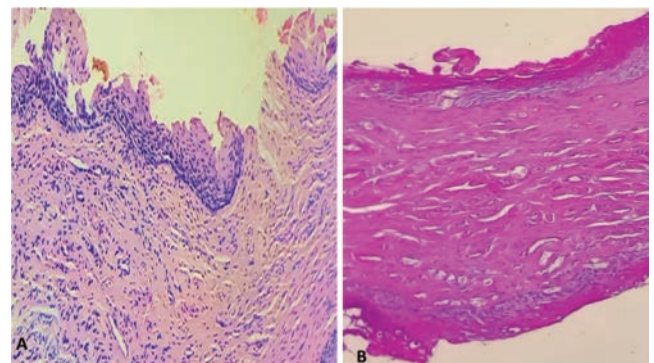
The patient was evaluated one month after the second injection.

Platelet-rich plasma was prepared by the double-centrifugation technique. Ten millilitres of whole blood were withdrawn into acid citrate dextrose (ACD) tubes and centrifuged by a at 2000 rpm for 5 minutes. The supernatant plasma was transferred into another sterile tube and centrifuged at 4000 rpm for 15 minutes to obtain a platelet concentrate. We added calcium gluconate for activation.<sup>15</sup> Platelet concentration were assessed in another sample obtained similarly to confirm successful preparation of more than one million/ $\mu$ L. We used a 3-ml syringe without needle as a vaginal applicator to deliver a mixture of topical lidocaine 2.5% and prilocaine 2.5% (pridocaine cream, Global Napi Pharmaceutical, Egypt) into the vestibule and the first 3 cm of vagina, 15 to 30 minutes before session. The treated area was cleaned with saline and sterilized with betadine. Three cubic centimetres of PRP mixed with 2ml of non-cross linked hyaluronic acid 3% (Simildiet Laboratories, Spain) in a 5mL syringe were injected submucosally every 5mm into the vestibule and the lower 3 cm of the lateral and posterior vaginal walls with 27-gauge needle and a 5-mL syringe.

The patient was assessed using the Arabic validated version of the female sexual function index<sup>16</sup> before treatment and 1 month after the second injection. Her pre-treatment scores were as follows; desire 1.8, arousal 3.6, lubrication 1.2, orgasm 3.2, satisfaction 3.2, pain 1.2, total 14.20. Post-treatment scores were as follows; desire 1.8, arousal 3.9, lubrication 6, orgasm 4.8, satisfaction 4.8, pain 4.8, total FSFI 26.1. Her index of sexual satisfaction score (ISS)<sup>17</sup> pre-treatment score of 77 was reduced to 65, and her male partner similarly showed a reduction of pre-treatment score of 33 to 28. Examination of her vaginal mucosa showed improvement of mucosa colour, integrity. She was satisfied by the treatment outcome and requested to continue monthly injections.

## Discussion

Modern treatment of Hodgkin's lymphoma (HL) has improved its prognosis, nevertheless patients frequently experience its delayed effects, including premature menopause.<sup>18</sup> ABVD is a chemotherapy regimen often used in the treatment of Hodgkin



**Figure 1.** A) Section showing marked atrophy of vaginal epithelium (thinning and flattening of non-keratinized stratified squamous epithelium) and loss of maturation (smaller cell size with less cytoplasm) on the surface. Lamina propria shows highly vascular fibrous tissue with increased hyalinization of collagen fibres. (Haematoxylin and Eosin, X400). B) PAS-stained section of vaginal mucosa showing a reduction of the positively stained glycogen containing cells. (PAS, X400).

lymphoma. The associated risk of premature menopause with the ABVD regimen is very low at around 2%.<sup>18</sup> The risk of early menopause however is more than 20-fold higher after ovarian radiotherapy, alkylating chemotherapy other than dacarbazine, or BEAM (bis-chloroethyl nitrosourea [BCNU], etoposide, cytarabine, melphalan) chemotherapy for stem cell transplantation. It has been shown that menopause also occurs sooner after ovarian radiotherapy (62.5% within five years of  $\geq 5$  Gy treatment) and BEAM (50.9% within five years) than after alkylating chemotherapy (24.2% within five years of  $\geq 6$  cycles).<sup>18</sup> The reported dyspareunia in our reported case is most likely secondary to vulvovaginal atrophy following pelvic radiotherapy.

The lower third of the anterior vaginal wall has been proved to have a higher density of nerves immunohistochemically (7,8,9) which it the most responsive to pressure during coitus. (6,10). PRP injections are associated with rejuvenating and regenerative effects as increasing collagen formation and neovascularization in the anterior vaginal wall<sup>19</sup> which makes the vagina more receptive during sexual arousal increasing vaginal fluid secretion and decreases vaginal dryness.<sup>19</sup> HA is also well-known for its water holding properties in topical lubricants or injections making it a potential tool in conditions such as dyspareunia.<sup>14</sup> The effects of PRP and HA combination contribute to the improvement observed in arousal, lubrication, pain, orgasm and satisfaction observed in our patient. The total FSFI score improved but was still below the cut off value for sexual distress. Greater improvement could require a greater number of injection sessions. Couple sexual satisfaction also improved probably secondary to orgasm achievement and better sexual function. There is no consensus in the literature about how many times and how often PRP-HA injections should be administered. We suggest that the frequency and number of injections are better tailored according to the patient's condition and observed improvement. Hersant *et al.*<sup>20</sup> reported the efficacy of PRP combined with hyaluronic acid in vulvovaginal atrophy in postmenopausal women with a history of breast cancer. Their patients reported improvement in the clinical symptoms of dyspareunia. This is the first report of effectiveness of combined PRP-HA injections after pelvic radiotherapy in a Hodgkin's lymphoma patient. Our findings are limited by being limited to the single case reported. Histologic evaluation and an immunoassay were not done as the patient refused taking a second biopsy. So, the exact mechanisms of PRP-HA were not objectively demonstrated. Further studies are needed to establish their efficacy are needed before the technique can become a reliable option in the management of the vaginal atrophy.

## Conclusions

We conclude that submucosal vaginal injections of PRP combined with non-cross-linked hyaluronic acid is a promising method to improve the hydration of vaginal mucosa and improve sex-related pain in postmenopausal Hodgkin's lymphoma survivors.

## References

- Ranger TA, Burchardt J, Clift AK, et al. Hormone replacement therapy and cancer survival: a longitudinal cohort study: protocol paper. *BMJ Open* 2021;11:e046701.
- Angelou K, Grigoriadis T, Diakosavvas M, et al. The Genitourinary syndrome of menopause: an overview of the recent data. *Cureus* 2020;12:e7586.
- D'Oria O, Giannini A, Buzzaccarini G, et al. Fractional CO<sub>2</sub> laser for vulvo-vaginal atrophy in gynecologic cancer patients: A valid therapeutic choice? A systematic review. *Eur J Obstet Gynecol Reprod Biol* 2022;277:84-9.
- Moral E, Delgado JL, Carmona F, et al. The impact of genitourinary syndrome of menopause on well-being, functioning, and quality of life in postmenopausal women. *Menopause* 2018;25:1418-23.
- The NGSMPSEP. The 2020 genitourinary syndrome of menopause position statement of The North American Menopause Society. *Menopause* 2020;27:976-92.
- Benini V, Ruffolo AF, Casiraghi A, et al. New innovations for the treatment of vulvovaginal atrophy: an up-to-date review. *Medicina (Kaunas)* 2022;58.
- Faubion SS, Larkin LC, Stuenkel CA, et al. Management of genitourinary syndrome of menopause in women with or at high risk for breast cancer: consensus recommendations from The North American Menopause Society and The International Society for the Study of Women's Sexual Health. *Menopause* 2018;25:596-608.
- Desai SA, Kroumpouzou G, Sadick N. Vaginal rejuvenation: From scalpel to wands. *Int J Womens Dermatol* 2019;5:79-84.
- Torella M, Del Deo F, Grimaldi A, et al. Efficacy of an orally administered combination of hyaluronic acid, chondroitin sulfate, curcumin and quercetin for the prevention of recurrent urinary tract infections in postmenopausal women. *Eur J Obstet Gynecol Reprod Biol* 2016;207:125-8.
- Schiavi MC, Porpora MG, Vena F, et al. Orally administered combination of hyaluronic acid, chondroitin sulfate, curcumin, and quercetin in the prevention of postcoital recurrent urinary tract infections: analysis of 98 women in reproductive age after 6 months of treatment. *Female Pelvic Med Reconstr Surg* 2019;25:309-12.
- Zheng Z, Yin J, Cheng B, Huang W. Materials selection for the injection into vaginal wall for treatment of vaginal atrophy. *Aesthetic Plastic Surg* 2021;45:1231-41.
- Saleh DM, Abdelghani R. Clinical evaluation of autologous platelet rich plasma injection in postmenopausal vulvovaginal atrophy: A pilot study. *J Cosmetic Dermatol* 2022;21:4269-75.
- Prodromidou A, Zacharakis D, Athanasiou S, et al. The emerging role on the use of platelet-rich plasma products in the management of urogynaecological disorders. *Surg Innov* 2022; 29:80-7.
- Zacharakis D, Pitsouni E, Grigoriadis T, et al. Minimal invasive procedures for the treatment of genitourinary syndrome of menopause (GSM). *Un update. HjoG* 2020;19:35-44.
- Combs MR, Denomme G, Grossman BJ, et al. In: Brecher ME, Leger RM, Roseff SD, editors. *AABB Technical Manual*. 15th ed: American Association of Blood Banks; 2005. p. 815-7.
- Anis TH, Gheit SA, Saied HS, Al kherbash SA. Arabic translation of Female Sexual Function Index and validation in an Egyptian population. *J Sex Med* 2011;8:3370-8.
- Attaky A, Schepers J, Kok G, Dewitte M. The role of sexual desire, sexual satisfaction, and relationship satisfaction in the sexual function of arab couples living in Saudi Arabia. *Sex Med* 2021;9:100303.
- Swerdlow AJ, Cooke R, Bates A, et al. Risk of premature menopause after treatment for Hodgkin's lymphoma. *J Natl Cancer Inst* 2014;106.
- Sukgen G, Ellibes Kaya A, Karagun E, Caliskan E. Platelet-rich plasma administration to the lower anterior vaginal wall to improve female sexuality satisfaction. *Turk J Obstet Gynecol* 2019;16:228-34.
- Hersant B, SidAhmed-Mezi M, Belkacemi Y, et al. Efficacy of injecting platelet concentrate combined with hyaluronic acid for the treatment of vulvovaginal atrophy in postmenopausal women with history of breast cancer: a phase 2 pilot study. *Menopause* 2018;25:1124-30.